



Journal of Health and Medical Sciences

Khan, Muhammad, Uzair, Muhammad, Yousaf, Junaid, Waqas, Abdul, Khalid, Shaheer, Haider, Syed Ijlal, Ijaz, Zainab, Arshad, Hafiza Tasmia, Gulzar, Javeria, Zafar, Shumaila, Aslam, Adina, Farooq, Syed Yousaf, Ehtisham-Ul-Haq, Hafiz, and Tahir, Muhammad Ahmad. (2019), Frequency of Correct Findings of Abdominal Ultrasonography Compared with CT Scan in Detection of Solid Intra-Abdominal Visceral Injuries. In: *Journal of Health and Medical Sciences*, Vol.2, No.3, 256-263.

ISSN 2622-7258

DOI: 10.31014/aior.1994.02.03.45

The online version of this article can be found at:
<https://www.asianinstituteofresearch.org/>

Published by:
The Asian Institute of Research

The *Journal of Health and Medical Sciences* is an Open Access publication. It may be read, copied, and distributed free of charge according to the conditions of the Creative Commons Attribution 4.0 International license.

The Asian Institute of Research *Journal of Health and Medical Sciences* is a peer-reviewed International Journal. The journal covers scholarly articles in the fields of Medicine and Public Health, including medicine, surgery, ophthalmology, gynecology and obstetrics, psychiatry, anesthesia, pediatrics, orthopedics, microbiology, pathology and laboratory medicine, medical education, research methodology, forensic medicine, medical ethics, community medicine, public health, community health, behavioral health, health policy, health service, health education, health economics, medical ethics, health protection, environmental health, and equity in health. As the journal is Open Access, it ensures high visibility and the increase of citations for all research articles published. The *Journal of Health and Medical Sciences* aims to facilitate scholarly work on recent theoretical and practical aspects of Health and Medical Sciences.



ASIAN INSTITUTE OF RESEARCH
Connecting Scholars Worldwide



Frequency of Correct Findings of Abdominal Ultrasonography Compared with CT Scan in Detection of Solid Intra- Abdominal Visceral Injuries

Muhammad Khan¹, Muhammad Uzair¹, Junaid Yousof¹, Abdul Waqas¹, Shaheer Khalid¹, Syed Ijlal Haider¹, Zainab Ijaz¹, Hafiza Tasmia Arshad¹, Javeria Gulzar¹, Shumaila Zafar¹, Adina Aslam¹, Syed Yousof Farooq¹, Hafiz Ehtisham-Ul-Haq¹, Muhammad Ahmad Tahir¹

¹ University Institute of Radiological Sciences & Medical Imaging Technology, The University of Lahore, Lahore, Pakistan

Correspondence: House No. 1231/59B, Street No. 1, Sabir Colony, Lakkar Mandi, Faizi Road, Multan.
E-mail: Muhammad.khan555666@gmail.com

Abstract

Background: Blunt abdominal trauma (BAT) is very common, the prevalence being 12–15%. Evaluation of patients with BAT is a challenge. This study aimed to compare the USG & CT with regards the frequency of correct findings in the detection of solid intra-abdominal injuries. **Objectives:** To determine the frequency of correct findings of abdominal ultrasonography compared with CT scan in the detection of solid intra-abdominal visceral injuries. **Methods:** The study was carried out at Radiology Department Nishtar Hospital, Multan & Children Hospital Multan, Pakistan, for a duration of six months with Eighty-eight patients selected using non-probability purposive sampling technique. **Results:** Mean age of the patients was 35.83±14.02 years. There were 75(85.2%) male and 13(14.8%) female in the present study, respectively. Ultrasonography detected abdominal injury in 49(55.7%) patients while it was detected in 59(67%) patients by computed tomography scan. Abdominal injury detected by both ultrasonography and computed tomography was 48 patients (true positive). Ultrasound sensitivity was revealed 81.36%, specificity 96.55%, diagnostic accuracy 86.36%, Positive predictive value 97.95%, and Negative predictive value 71.79%. **Conclusion:** CT scan is the gold standard modality for blunt abdominal trauma, whereas ultrasound can be used as the first-line modality in the patients of blunt abdominal trauma.

Keywords: Intra-Abdominal Visceral Injuries, Ultrasonography, Computed Tomography Scan

Introduction

Because of its large surface area, the abdomen is one of the most commonly injured regions of the body (Khan JS, Iqbal N, Gardezi JR, 2006). Blunt abdominal trauma (BAT) is very common, and the prevalence of intra-abdominal injury has been reported to be as high as 12–15% (Kendall JL, Kestler AM, Whitaker KT, Adkisson MM, Haukoos JS, 2011). The mechanisms resulting in abdominal injuries were motor vehicle collision (73%), motorcycle collision (7%), auto-pedestrian collision (6%), and fall (6%) or during sports (Kendall JL, Kestler

AM, Whitaker KT, Adkisson MM, Haukoos JS, 2011, GM Khan Baluch, 2001). Other likely causes are recreational or industrial etiologies.

Prevalence of intra-abdominal injuries (IAI) varies widely, ranging from 7.7% to 65% (Brown CK, Dunn KA, Wilson K, 2000). Among the most commonly injured organs that may be affected are the spleen, liver, retroperitoneum, kidneys, small bowel, bladder, colon, diaphragm, and pancreas. The frequency has been reported as the spleen (40-55%), liver (35-45%), pancreas (29%), kidneys (11%) and small bowel loops (5-10%) (Weishaupt D, Grozaj AM, Willmann JK, Roos JE, Hilfiker PR, Maricenk B, 2003).

Assessment of patients who've sustained abdominal trauma may pose a good-sized diagnostic assignment to the most seasoned trauma surgeon to decide the extent of an abdominal injury and the want for surgical intervention on the premise of clinical presentation alone (Khan JS, Iqbal N, Gardezi JR, 2006). Speedy diagnosis is essential (Richards JR, Knopf NA, Wang L, McGahan JP, 2002) and accurately prioritizing diagnostic workup and treatment is vital to ensure affected person's survival (Shafiq M, Khokhar RA, 2001) especially for people with volatile hemodynamics, the avoidance of needless surgical procedures with its invasiveness and complications must additionally be considered. The morbidity and mortality may also increase drastically in case of blunt abdominal trauma if there is any delay in early diagnosis and prompt treatment. It can result in 25–35% deaths if no longer diagnosed and treated early.

Ultrasonography (US) is taken into consideration as the number one modality of choice for assessment of intra abdominal injuries due to blunt abdominal trauma. Other diagnostic modalities consist of computed tomography (CT) and diagnostic peritoneal lavage (DPL) (Fienstein AJ, McKenney MG, Cohn SM, 2004). Plane X-ray abdomen in the supine position is highly sensitive (85%) in the detection of pneumoperitoneum, which shows gastrointestinal perforation (Sahu SK, Husain M, Sachan PK, 2008). However, radiography isn't feasible in all instances of BAT. Moreover, in pregnant women; radiation exposure might prove teratogenic (Ghaffar A, Siddiqui TS, Haider H, Khatri H, 2008).

Ultrasonography is a noninvasive, speedy, accurate, portable, rather in the inexpensive examination, serial examinations can be executed, and it can be carried out in unstable patients at some point of resuscitation. It may rapidly be done on the bedside even without interrupting resuscitation (Moriwaki Y, Sugiyama M, Toyoda H, Kosuge T, Arata S, Iwashia M, 2009). Limitations of ultrasonography include its dependence on operator's competencies, its usage in obese patients wherein it is able to be difficult for adequate evaluation of organ parenchyma and its limited ability to locate bowel and mesenteric injury (Pathan A, 2005). It is also beneficial as a preliminary rapid screening procedure in abdominal injuries for surgeon decision making during resuscitation (Naeem M, Syed A, Razwan Q, Panazai AM, Ahmed J). USG has been described as an accurate technique for the detection of hemoperitoneum in adults (Richards JR, Knopf NA, Wang L, McGahan JP, 2002). Overall, sonography has sensitivity among 71% and 88%, specificity between 92% and 97%, and is 91% to 96% accurate (Brenchley J, Walker A, Sloan JP, Hassan TB, Venables H, 2006).

In hemodynamically stable patients of blunt abdominal trauma, the diagnostic modality of choice is CT, which is considered gold standard radiographic modality having a sensitivity of 100%.

Ultrasonography is a rapidly expanding modality in our country and has been widely used in the evaluation of the abdominal trauma patients as focused abdominal sonography (Amer MS, Ashraf M, 2008). The advent of newer imaging techniques with high-resolution Computerized Tomography (CT) scanners has enabled the clinicians to exactly diagnose the extent of the intra-abdominal injuries. This study aimed to find the frequency of correct findings of ultrasonography in the detection of solid intra-abdominal injuries. This would help to establish USG as an aid in early triage of patients for speedy management decision-saving time and reducing patient mortality as well as cost.

Methods

It was a cross-sectional comparative study carried out in Radiology Department Nishtar Hospital, Multan & Children Hospital Multan, Pakistan, for six months during the period of 1st July 2018 to 31st December 2018.

Eighty-eight subjects were selected by non-probability purposive sampling on the basis of history and clinical examination. Subjects included both male and female gender, age 16-70 years. Post-operative, pregnant females were excluded. TOSHIBA XARIO (Model: SSA-660) and ALOKA SSD-3500 were used for sonography using 2.5–5.0 MHz convex probe and CT scans of the abdomen were done on spiral CT scan (Model: TOSHIBA, AQUILION, 4,16 and 64 slices taking (> 200 ml) free fluid in the peritoneal cavity as a positive finding. Descriptive statistics were calculated for the patient's age. Frequencies and percentages were calculated for gender and correct findings of USG in the detection of intra-abdominal injury. Sensitivity, specificity, diagnostic accuracy, positive and negative predictive values were calculated taking CT as the gold standard.

Results

Mean age of the patients was 35.83±14.02 years. Most frequent age group was 15–30 years having 36(40.9%) subjects. There were 29(33%) patients of the age of 31–45 years. There were 19(21.6%) subjects of the age of 46–60 years followed by 4(4.5%) subjects of the age of 61 and above as (Table No.1). There were 75(85.2%) male and 13(14.8%) female in the study, respectively (Figure No.1).

Abdominal injury detected by ultrasonography was in 49(55.7%) patients while it was in 59(67%) patients as detected by computed tomography. (Table No. 2 & 3).

Type of injury detected by ultrasound was depicted as kidney 5(10.2%), liver 15(30.6%), pancreas 10(20.4%), small bowel 3(6.1%), spleen 16(32.7%). While the type of injury as revealed by computed tomography was kidney 7(11.9%), liver 24(40.7%), pancreas 10(16.9%), small bowel 3(5.1%) and spleen 15(25.4%) as mentioned in Table No. 4 & 5.

Sonographic scans detected abdominal injuries in 17(35.4%) patients between 15–30 years, followed by 15(31.3%) patients between 31–45 years of age. There were 13(27.0%) patients in 46–60 years age group and 3(6.3%) patients having age 61 years and above (Table No. 6). Ultrasonography scans revealed 43(89.6%) males and 5(10.4%) females with abdominal trauma out of 48 trauma patients (Table No. 7).

There were 48 True positives, 1 false positive, 11 false negatives, and 28 true negative cases. This study revealed ultrasound sensitivity 81.36%, specificity 96.55%, diagnostic accuracy 86.36%, Positive predictive value 97.95%, and Negative predictive value 71.79%.

Table 1. Age Distribution of Patients Presented with Abdominal Trauma

Age (in years)	No. of Patients	Percentage (%)
15 — 30	36	40.9
31 — 45	29	33.0
46 — 60	19	21.6
61 and above	4	4.5
Total	88	100.0

Figure 1: Gender Distribution of Patients Presented with Abdominal Trauma

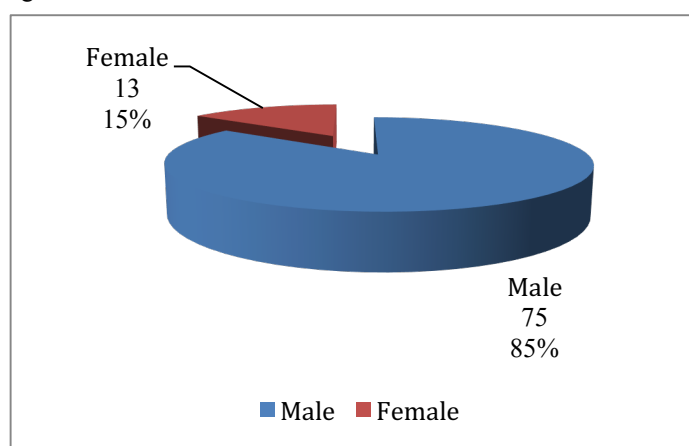


Table 2. Abdominal Injury Detected on Ultrasound in Patients Presented with Abdominal Trauma

Presence of Abdominal Injury	No. of Patients	Percentage (%)
Yes (free fluid > 200 ml)	49	55.7
No	39	44.3
Total	88	100.0

Table 3. Abdominal Injury Detected on Computed Tomography in Patients Presented with Abdominal Trauma

Presence of Abdominal Injury	No. of Patients	Percentage (%)
Yes (free fluid > 200 ml)	59	67.0
No	29	33.0
Total	88	100.0

Table 4. Types of Injury Detected in the US in Patients Presented with Abdominal Trauma

Type of Injury	No. of Patients	Percentage (%)
Kidney	5	10.2
Liver	15	30.6
Pancreas	10	20.4
Small bowel	3	6.1
Spleen	16	32.7
Other	0	0.0
Total	49	100.0

Table 5. Types of Injury Detected on Computed Tomography Scan in Patients Presented with Abdominal Trauma

Type of Injury	No. of Patients	Percentage (%)
Kidney	7	11.9
Liver	24	40.7
Pancreas	10	16.9
Small bowel	3	5.1
Spleen	15	25.4
Other	0	0.0
Total	59	100.0

Table 6. Age Distribution in Relation to Outcome on Ultrasound in Patients with Abdominal Trauma

Age (in years)	No. of Patients with Abdominal Injury (TP)	Percentage (%)
15 — 30	17	35.4
31 — 45	15	31.3
46 — 60	13	27.0
61 and above	3	6.3
Total	48	100.0

Table 7. Gender Distribution in Relation to Outcome on Ultrasound in Patients with Abdominal Trauma

Sex	No. of Patients with abdominal injury (TP)	Percentage (%)
Male	43	89.6
Female	5	10.4
Total	48	100.0

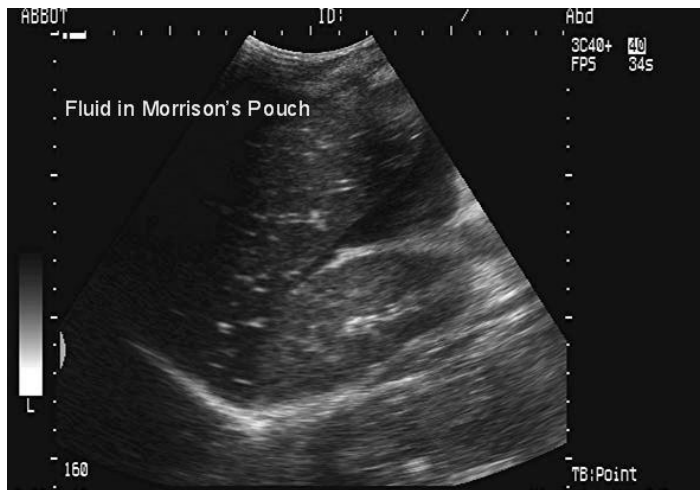


Figure 1. Blunt abdominal trauma. Free fluid in Morison pouch.

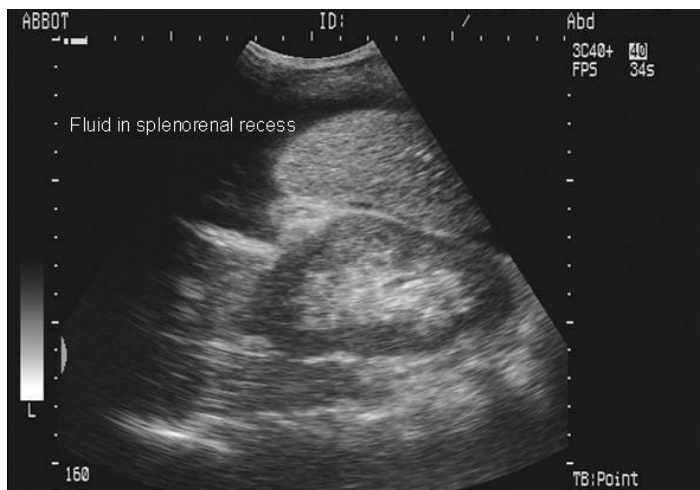

Figure 2. Blunt abdominal trauma. Free fluid in splenorenal recess.

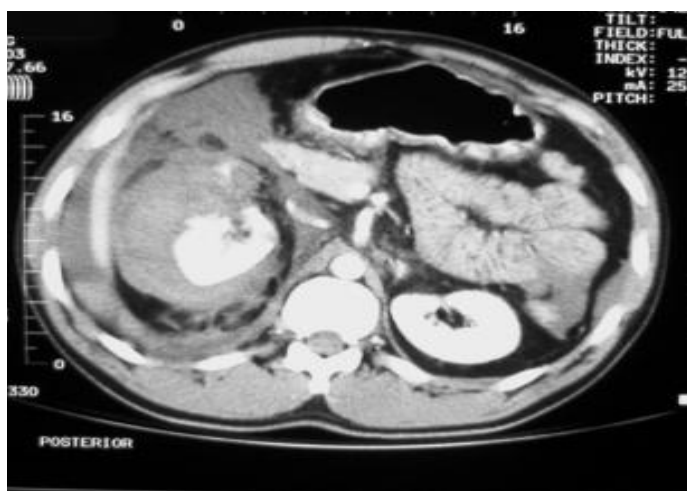


Figure 3. Blunt abdominal trauma. CT shows right kidney injury with blood in perirenal space. The injury resulted from a high-speed motor vehicle collision.

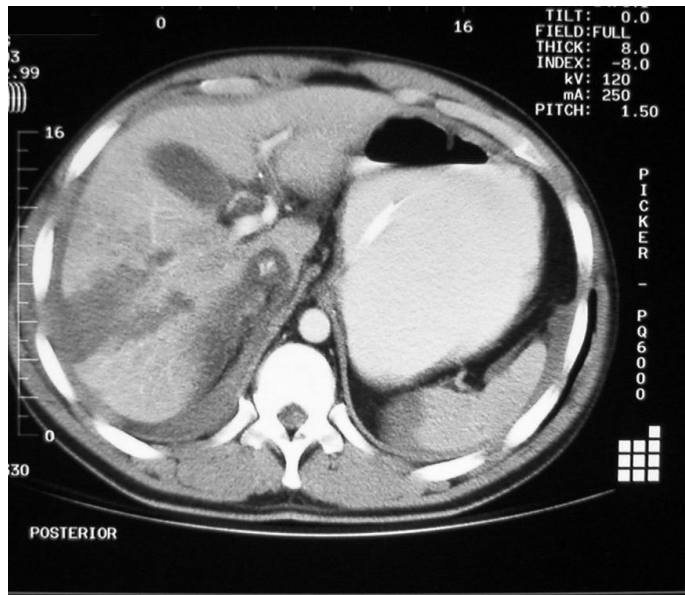


Figure 4. Tomography shows blunt abdominal trauma with a liver laceration.

Discussion

Trauma is the most common reason of death within the populace between the ages of 1 & 40 years globally. Abdominal trauma ranks third as a cause of traumatic deaths, after head and chest injuries. The majority of abdominal injuries are because of blunt trauma (Kudera JS, Aanning HL, 2004). The choice of the right approach on the proper time is vital in the treatment of patients with blunt abdominal trauma. A dependable, bedside, monetary, and rapidly performed screening test can be pivotal. Diagnosis of abdominal trauma patients possesses a clinical problem due to the reality that maximum patients have more than one organ injuries. Modifications visible within the degree of consciousness further complicate this problem. This requires the need of repeated assessment of the patient, along with a trauma screen including X-ray abdomen and chest, abdominal ultrasound (US) to see free fluid in the peritoneum (Styner JK, 2006). The use of screening sonography for abdominal trauma has had encouraging results in recent years. Sonography is a quickly performed, rapidly interpreted, noninvasive, inexpensive, and portable (or even handheld) tool. Sonography does not interfere with resuscitation efforts and, very important, will not influence subsequent CT. Emergency physicians, trauma surgeons, and radiologists can detect very small amounts of hemoperitoneum near the site of bleeding and within the dependent peritoneal spaces (Paaajnen H, Lahti P, Nordback I, 1999).

The present study was designed to determine the frequency of correct findings of abdominal ultrasonography compared with CT scan in the detection of solid intra-abdominal visceral injuries. The results of the present study coincide with local and international literature. In the present study, an ultrasound revealed a sensitivity of 81.36%, specificity 96.55%, diagnostic accuracy 86.36%, Positive predictive value 97.95%, and Negative predictive value 71.79%.

In a similar study comparing USG and CT scan conducted by Mohsin et al (Mohsin N, Jesrani A, Mahmud R, Nizamani WM, Ali M, 2018), blunt abdominal trauma was diagnosed by ultrasound scan in 72 (72%) [37 males & 35 females] patients ($p=0.844$) and by CT scan in 74 (74%) [41 males & 33 females] patients ($p=0.250$). As per comparison of ultrasound findings, 68 (68%) [35 males & 33 females] patients had true positive, 22 (22%) [9 males & 13 females] had true negative diagnosis, 04 (4%) [2 males & 2 females] had false-positive diagnosis and 06 (6%) [6 males] patients had false-negative diagnosis of blunt abdominal trauma, as compared to the CT scan ($p=0.084$). The sensitivity of ultrasonography in the diagnosis of injuries in blunt abdominal trauma was 91.9%, specificity was 84.6%, positive predictive value was 94.4%, negative predictive value was 78.6%, and accuracy was 90% in the diagnosis of injuries in blunt abdominal trauma.

Nirav Patel et al. have reported overall sensitivity 57.48%, specificity 97.77%, positive predictive value 88.9125, negative predictive value 97.185, and accuracy of 90.75% of US in the detection of intra-abdominal injuries. CT

scan showed the highest sensitivity of 95.35%, specificity of 100%, the positive predictive value of 100%, negative predictive value 77.78% and accuracy 96% (Patel N, Domadia N, Konark, 2015).

Cheung Kent Shek et al determined diagnostic accuracy of Focused Abdominal Sonography for Trauma in blunt abdominal trauma patients and found sensitivity, specificity, positive PV, negative PV, positive LR, negative LR and accuracy of USG were 50.0%, 97.3%, 87.0%, 84.6%, 18.8, 0.51 and 85.0% respectively (Shek CK, Tai WH, Pong LL, Chi TT, Kit LGK, 2012).

Saira Hamid et al diagnostic accuracy of ultrasound of visceral injury in blunt abdominal trauma and analyzed sensitivity of ultrasound was 93.5%, specificity was 84.8%, Positive predictive value was 82.8%, Negative predictive value was 94.3% while diagnostic efficacy was 88.65% (Hamid S, Rasheed N, Rani F, 2014).

Atif Latif and Associates in a local study, evaluated the diagnostic value of USG in abdominal injuries. USG examinations were positive in 34 patients. True-positive findings were seen in 28(82.35%) of these on CT and/or laparotomy. There were two false-negative cases. Sensitivity, specificity, positive predictive value, negative predictive value and accuracy of USG in detecting intra-abdominal injury were 93.3%, 85.0%, 82.3%, 94.4%, and 88.5%, respectively (Latif A, Farooq MA, Azhar MA, 2008).

Nizamuddin Memon et al. determined the role of USG & CT scan in blunt abdominal trauma. Ultrasonography was found to be 96.97% sensitive and 100% specific in detecting haemoperitoneum, whereas it was 82.47% sensitive and 100% specific in diagnosing visceral injuries. They concluded that ultrasound and CT scan play an important role in making appropriate decision to select management option for patients with blunt abdomen trauma (BAT) and can reduce negative laparotomy rate (Memon N, Sheeba A, Memon K, 2009).

Mohapatra et al. found that abdominal ultrasonography had a sensitivity of 89%, the specificity of 100%, and accuracy of 100% in diagnosing abdominal solid visceral injuries (Mohapatra S, Pattanayak SP, Rao KRRM, 2003).

Saleh M. Al-Salamah et al. in a study at Saudi Arabia evaluated the role of ultrasonography, computed tomography, and diagnostic peritoneal lavage in abdominal trauma. Sensitivity and accuracy of all 3 examinations, DPL, USG, and CT were comparable (98%, 96%, 98% and 92%, 95%, 99%) respectively (Al-Salamah SM, Mirza SM, Ahmad SN, Khalid K, 2002).

Ravindernath ML and Reddy GM while comparing the efficacy of CT scan and ultrasound in patients with blunt abdominal trauma determined 49 patients (87.5%) were detected by ultrasound, and 7 (12.5%) were missed. However, only 1 case (1.8%) was missed by CT scan, thereby having a sensitivity of 98.2% (Ravindernath ML, Reddy GM, 2017).

The variations in results of ultrasound in these studies are due to several factors, including the examination technique and extent of sonography, the operator's experience, and the reference tool used (patient's course, diagnostic peritoneal lavage, or CT and laparotomy).

Conclusion

CT scan is the gold standard modality for blunt abdominal trauma, whereas ultrasound can be used as the first-line modality in the patients of blunt abdominal trauma.

References

- Al-Salamah SM, Mirza SM, Ahmad SN, Khalid K. Role of ultrasonography, computed tomography, and diagnostic peritoneal lavage in abdominal blunt trauma. *Saudi Med J.* 2002;23:1350-5.
- Amer MS, Ashraf M. Role of FAST and DPL in assessment of blunt abdominal trauma. *Professional Med J.* 2008;15:200-4.

- Baluch GM. Diagnostic value of ultrasound in blunt abdominal trauma. *J Surg Pakistan*. 2001;6:23-5.
- Brown CK, Dunn KA, Wilson K. Diagnostic evaluation of patients with blunt abdominal trauma: a decision analysis. *Acad Emerg Med*. 2000;7:385-96.
- Brenchley J, Walker A, Sloan JP, Hassan TB, Venables H. Evaluation of focused assessment with sonography in trauma (FAST). *Emerg Med J*. 2006;23:446-8.
- Ghaffar A, Siddiqui TS, Haider H, Khatri H. Postsurgical pneumoperitoneum – comparison of abdominal ultrasound findings with plain radiography. *Journal of the College of Physicians and Surgeons Pakistan* 2008;18:477-480.
- Fienstein AJ, McKenney MG, Cohn SM. Evaluating an ultrasound algorithm for patients with blunt abdominal trauma. 16-18 Aug 2004. RTO-MP-HFM-109; P6-1-10.
- Kendall JL, Kestler AM, Whitaker KT, Adkisson MM, Haukoos JS. Blunt abdominal trauma patients are at very low risk for intraabdominal injury after emergency department observation. *West J Emerg Med* 2011;12(4):496–504.
- Khan JS, Iqbal N, Gardezi JR. Pattern of visceral injuries following blunt abdominal trauma in motor vehicular accidents. *J Coll Physicians Surg Pak*.2006;16:645-7.
- Latif A, Farooq MA, Azhar MA. Diagnostic value of ultrasonography in evaluation of blunt abdominal trauma. *Rawal Med J*. 2008;33(2):154-8.
- Kudera JS, Aanning HL. Damage control for blunt hepatic trauma: case presentation and historical review. *S D J Med* 2004; 57:449-53.
- Mazhar Naeem, Anjum Syed, Qazi Razwan, Amin Muhammad Panazai, Jamil Ahmed. Role of Ultrasonography in blunt abdominal injury. *Mother & Child* 1999;37: 27-31.
- Memon N, Sheeba A, Memon K. Role of ultrasonography & CT scan in blunt abdominal trauma (BAT). *J Liaquat Uni Med Health Sci* 2009;08:41-5.
- Mohapatra S, Pattanayak SP, Rao KRRM. Options in the management of solid visceral injuries from blunt abdominal trauma. *Indian J Surg* 2003;65:263–8.
- Mohsin N, Jesrani A, Mahmud R, Nizamani WM, Ali M. Evaluation of Injuries in Patients with Blunt Abdominal Trauma by Ultrasonography taking Computerized Tomography as Gold Standard Imaging Modality-Experience at Liaquat National Hospital. *J Liaquat Uni Med Health Sci*. 2018;17(01):42-6.
- Moriwaki Y, Sugiyama M, Toyoda H, Kosuge T, Arata S, Iwashia M, et al. Ultrasonography for the Diagnosis of Intraperitoneal Free Air In Chest-Abdominal -Pelvic Blunt Abdominal and Critical Acute Abdominal Pain. *Arch Surg* 2009;144: 137-41.
- Nirav Patel, Niket Domadia, Konark Assessment with Sonography for Trauma (FAST) and CT scan in abdominal trauma: Radiologist's perspective. *IAIM*, 2015; 2(6): 123-35.
- Paajnen H, Lahti P, Nordback I. Sensitivity of transabdominal ultrasonography in detection of intraperitoneal fluid in humans. *Eur Radiol* 1999;9:1423–5.
- Pathan A. Role of ultrasound in the evaluation of blunt abdominal trauma. *J Liaquat Uni Med Health Sci*. 2005;4(1):23-8.
- Ravindernath ML, Reddy GM. Comparison of efficacy of CT scan and ultrasound in patients with blunt abdominal trauma. *Int J Adv Med* 2017;4:370-4.
- Richards JR, Knopf NA, Wang L, McGahan JP. Blunt abdominal trauma in children: evaluation with emergency US. *Radiology* 2002;222:749-54.
- Sahu SK, Husain M, Sachan PK. Spontaneous Pneumoperitoneum: A Surgeon's Dilemma. *The Internet Journal of Surgery* 2008;15:2.
- Saira Hamid, Noreen Rasheed, Fouzia Rani. Diagnostic Accuracy of Ultrasound in Detection of Visceral Injury in Blunt Abdominal Trauma. *P J M H S VOL. 8 NO.4 OCT – DEC 2014*. 959-62.
- Shafiq M, Khokhar RA. Blunt abdominal trauma: diagnostic modalities and management. *J Surg* 2001;23-24:4-9.
- Shek CK, Tai WH, Pong LL, Chi TT, Kit LGK. Diagnostic accuracy of Focused Abdominal Sonography for Trauma in blunt abdominal trauma patients in a trauma centre of Hong Kong. *Chin J Traumatol* 2012;15(5):273-278.
- Styner JK. The birth of advance trauma life support (ATLS) Surgeon. 2006;4:163-5.
- Weishaupt D, Grozaj AM, Willmann JK, Roos JE, Hilfiker PR, Maricenk B. Traumatic injuries: imaging of abdominal and pelvic injuries. In: Baert AL, Gourtsoyannis N, editors. *Categorical course ECR*. Vienna, Australia: European Congress of Radiology; 2003. p.123-39.