



# Journal of Health and Medical Sciences

**Saleem, Sana, Qaiser, Rimshaw, Sadique, Aniq, Yousaf, Rabia, Andaleb, Sana, Bacha, Raham, Manzoor, Iqra, and Shaheen, Sajid. (2019), Sonographic Determination of Common Breast Pathologies in Married Women. In: *Journal of Health and Medical Sciences*, Vol.2, No.4, 503-508.**

ISSN 2622-7258

DOI: 10.31014/aior.1994.02.04.78

The online version of this article can be found at:  
<https://www.asianinstituteofresearch.org/>

Published by:  
The Asian Institute of Research

The *Journal of Health and Medical Sciences* is an Open Access publication. It may be read, copied, and distributed free of charge according to the conditions of the Creative Commons Attribution 4.0 International license.

The Asian Institute of Research *Journal of Health and Medical Sciences* is a peer-reviewed International Journal. The journal covers scholarly articles in the fields of Medicine and Public Health, including medicine, surgery, ophthalmology, gynecology and obstetrics, psychiatry, anesthesia, pediatrics, orthopedics, microbiology, pathology and laboratory medicine, medical education, research methodology, forensic medicine, medical ethics, community medicine, public health, community health, behavioral health, health policy, health service, health education, health economics, medical ethics, health protection, environmental health, and equity in health. As the journal is Open Access, it ensures high visibility and the increase of citations for all research articles published. The *Journal of Health and Medical Sciences* aims to facilitate scholarly work on recent theoretical and practical aspects of Health and Medical Sciences.



ASIAN INSTITUTE OF RESEARCH  
Connecting Scholars Worldwide



# Sonographic Determination of Common Breast Pathologies in Married Women

Sana Saleem<sup>1</sup>, Rimshaw Kaiser<sup>1</sup>, Aniq Sadique<sup>1</sup>, Rabia Yousaf<sup>1</sup>, Sana Andaleb<sup>1</sup>, Raham Bacha<sup>1</sup>, Iqra Manzoor<sup>1</sup>, Sajid Shaheen<sup>1</sup>

<sup>1</sup> University Institute of Radiological Sciences and Medical Imaging Technologies, Faculty of Allied Health Sciences, University of Lahore, Lahore, Pakistan

Corresponding Author: Sana Saleem, 332 Shaheen Block Bahria Town Lahore, Lahore Pakistan. Mobile: +92 304 4867231 E-mail: sanasaleem791@gmail.com

## Abstract

**Background:** In women, breast masses are getting progressively increasing across the board because of their mortality. Women are at high hazard in view of breast sicknesses, all the more ordinarily in instances of breast malignant growth. In numerous places of the world, breast carcinoma characterizes top in dangerous tumors affecting ladies with breast malignancy rates going from 1 to 8. By 2020, 70% of the 15 million new yearly malignancy injured individuals will be in creating nations. In the evaluation of clinically prevailing breast masses, ultrasound is a relatively moderate and effectively accessible symptomatic methodology that can be utilized clinically. The point of this exploration is to discover the accuracy of ultrasound in the determination of prevailing breast masses. **Objective(s):** To determine common breast pathologies with ultrasound in married women. **Methodology:** Ultrasound was done by using GE LOGIQ V5 and GE V SCAN with transducer (7-13) MHz in Radiology Department of Shaikh Zayed Hospital, Lahore. From October 2018 to September 2019, 138 patients were collected through convenient sampling with the request of breast ultrasound. Statistical software (SPSS version 22.0) is used for the analysis of data. **Results:** This study was done by using Ultrasound with 7-13 MHz of transducer. Data of total 138 patients were recorded for this study. Ultrasound was performed and the findings were analyzed. Out of 138 patients, The Ultrasonographic findings and frequency came out to be: Calcific foci 1, Cystic lesion 2, Hypoechoic nodules 1, Abscesses 1, Calcific foci 2, Calcific foci with lymph node 1, Cyst with ductal ectasia 1, Cystic lesion 29, Cystic lesion & calcific foci 1, Cystic lesion with ductal ectasia 4, Cystic lesion with intramammary lymph node 1, Cystic lesion with left axillary lymph node 1, Cystic lesion with right axillary lymph node 2, Cystic lesion with right axillary lymph node 2, Ductal ectasia 10, Ductal ectasia cystic lesion with left axillary lymph node 1, Ductal ectasia hypo echoic nodules cystic lesion with left axillary lymph node 1, Ductal ectasia with left axillary lymph nodes 1, Ductal ectasia with right axillary lymph node 2, Echogenic nodule 5, Fibro adenoma 5, Fibro adenoma with intramammary lymph node 1, Hypo echoic nodules 11, Hypo echoic nodules with ductal ectasia 1, Hypo echoic nodules with right axillary lymph node 1, Left axillary lymph node 6, Lymph nodes 2, Macro calcifications 1, Macro calcifications with hypo echoic nodule 1, Right axillary lymph node 11, Right Intra-mammary lymph node 1, Solid lesion 27, Solid lesion with micro calcifications 1. Out of 138, only 3 women were breast feeders. According to this study, 57 patients had left-sided breast pathologies, and 81 had right-sided breast pathologies. **Conclusion:** Palpable breast masses could easily be characterized and localized with the help of a relatively inexpensive and a more accessible ultrasound modality. It should be the first-line investigation in women of all ages.

**Keywords:** Ultrasonography, Breast Lesions, Breast Pathologies, Palpable Masses, Malignant Lesions

## Introduction

Breast disorders are a diverse group of illnesses leading to life-threatening cancers encountered commonly in the general population worldwide. (Rasheed et al., 2014) These escalating ubiquities of breast diseases lead to community consciousness to lower the stigma of breast cancer through education (Parkin et al., 2005). The primary cause of breast disorders in females is benign breast diseases that are non-cancerous and not life-threatening, commonly affecting women of reproductive age group however they may be bothersome or uncomfortable for some women associated with symptoms (Hatim et al., 2017). Benign breast diseases include pathologic changes in which the risk for developing breast cancer does not increase with the exception of lesions which are further divided into proliferative breast lesions without atypia and proliferative breast lesions with atypia that may confer a slight increase in risk (Ongore et al., 2013). Nonmalignant conditions like breast abscess, benign tumors, trauma, mastalgia, mastitis, nipple discharge, and fibrocystic changes may account for benign breast diseases that are prevailing worldwide (Chalya et al., 2016). Benign breast diseases are not only confined to fibro adenomas, fibrocystic diseases, cysts and ductal perforations with or without atypia. Some studies have shown 4-5 fold increased risk of developing breast cancer demonstrating benign breast diseases with atypia and 1.5-2 fold increased risk in patients without atypia (Silvera et al., 2008). Morphologically, from normal terminal ductal lobule to precancerous condition of breast and cancer which is spread and cancer which is not spread has been well described, however, the main genesis of benign breast disease is still undetermined (Wellings et al., 1975). There are certain factors that may contribute in development of benign lesions including, environmental and genetic predisposition element like diet, physical activity and alcohol (Berryhill et al., 2012). Although benign breast diseases are not life threatening still they are known to be a great reason for occurrence of cancer of breast (Dyrstad et al., 2015). According to some studies high risk of breast cancer is due to the history of family (Zhou et al., 2011). The general symptoms linked with cancer of breast may include pain, palpable mass, breast lumps however other clinical features may also be encountered including nipple discharge, nipple deformity, retraction and other skin changes (Chalya et al., 2016). Breast masses are named either threatening tumors or benevolent developments and masses (Devolli-Disha et al., 2009). Malignant breast lesions are of great concern because in women, breast cancer is the popular pathology, however, than malignant one benign breast lesions are quite a lot (Caleffi et al., 2004). Fibroadenoma could be a kind of noncancerous breast lump. It contains of each stromal and animal tissue parts (Rangaswamy and Rubby, 2016). When put next to healthy people among constant age teams, fibro adenoma as a non-cancerous breast mass has been considered to increase the chance of carcinoma (Prasad and Houserkova, 2007b). Fibro adenoma is associate estrogen-induced neoplasm that forms in teenage years. It is the third commonest breast lesion when fibrocystic sickness and malignant neoplastic disease (Valea and Katz, 2007). Breast fibro adenoma (FA) is a nonmalignant tumor, most often diagnose during self-examination or clinical breast examination(Larsen et al., 2003). It happens in 25% of symptomless girls (El-Wakeel and Umpleby, 2003). It's sometimes a sickness of early fruitful life; the high rate is between the era of 15 and 35 years. Conventionally considered a neoplasm of the breast, fibroadenoma is additionally thought to describe a collection of hyperplastic breast lobules known as "aberrations of traditional development and involution" (El-Wakeel and Umpleby, 2003). Fibroadenoma originates from the particular stroma of the lobe. About 50% of fibroadenomas contain different numbers of breast changes comparable to duct epithelial hyperplasia, sclerosing glandular disease and adenosis. Complicated fibroadenomas is that which contain these parts. Simple fibroadenomas don't seem to be related to any accrued risk for resulting carcinoma. However, ladies with complicated fibroadenomas could have a rather increase risk for resulting cancer (Carter et al., 2001). The presence of atypia (either ductal or lobular) restricted to a adenoma doesn't cause a larger risk for long breast malignant neoplastic disease than with fibroadenomas generally (Carter et al., 2001). Ultrasonography plays a main role in finding of breast pathologies with respect to the shape, contour, echo texture, echogenicity and encompassing tissue of the tumors, cysts and abscesses that square measure higher differentiate from nonmalignant tumor by ultrasound imaging; however, overlapping findings in non-solid fibroadenomas at the facet of occasional calcification and non-circumscribed margins may mimic the findings in many alternative forms of breast masses (Prasad and Houserkova, 2007a).

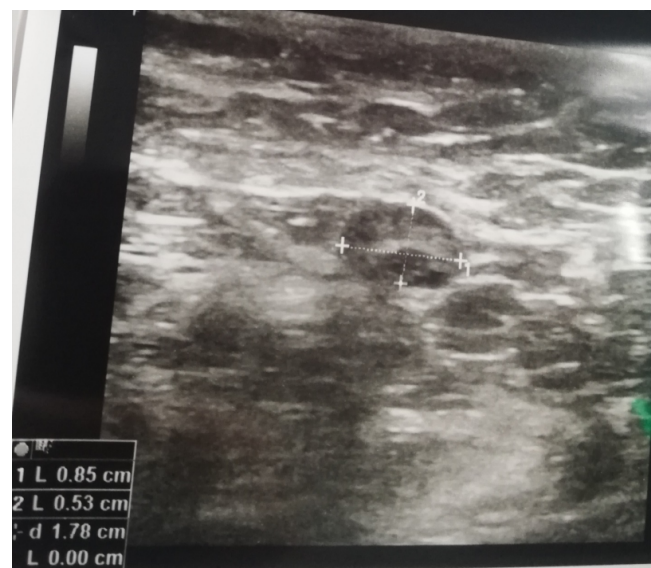
Image 1: Sonographic Image of 65 years old Basheeran bibi showing irregular hypochoic malignant lesion measuring 16\*14 mm in axillary tail.

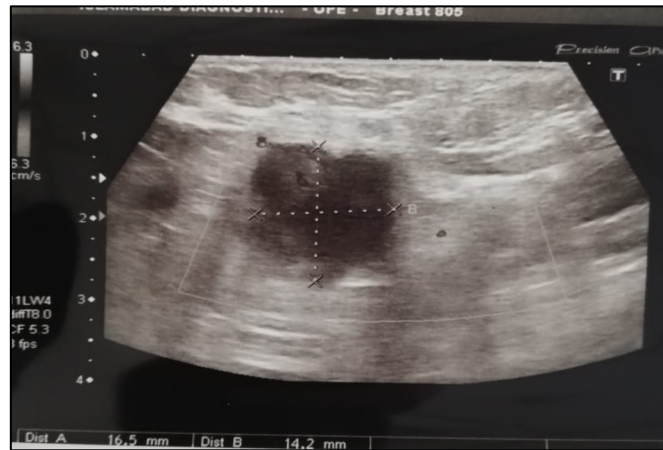

Image 2: Sonographic image of 47 years old Miss Saima showing lesion with homogenous echotexture measuring 17.3\*12.6 mm in Right Breast.

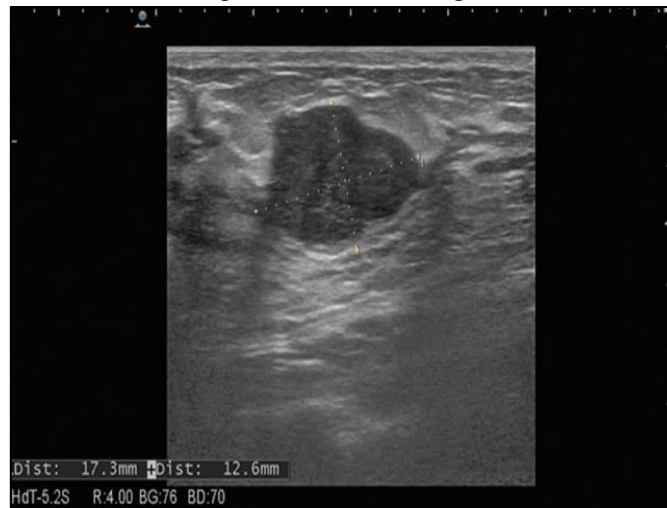

Image 3: Sonographic image of 29 years old Miss Zunaira showing lymph nodes in axilla measuring 8.5\*5.3mm in the left breast.



## Results

138 patients in total with mean age  $38.62 \pm 13.07$  years were included in the study. Out of 138 patients, The Ultrasonographic findings in the form of its frequency and percentage are given in table 1. Out of 138, only 3 women were breast feeders. According to this study, 57 (41.3) patients had left-sided breast pathologies and 81(58.7) had right sided breast pathologies. Right side was more involved in breast masses as compared to left; right to left ration is 57(41.30%) to 81(58.70%).

Table 1: Ultrasound findings in the patients of palpable breast masses

Ultrasound Findings	Frequency	Percent
Calcific foci	1	0.7
Cystic lesion	2	1.4
Hypoechoic nodules	1	0.7
Abscesses	1	0.7
Calcific foci	2	1.4
Calcific foci with right axillary lymph node	1	0.7
Cyst with ductal ectasia	1	0.7
Cystic lesion	29	20.7
Cystic lesion & calcific foci	1	0.7
Cystic lesion with ductal ectasia	4	2.9
Cystic lesion with intramammary lymph node	1	0.7
Cystic lesion with left axillary lymph node	1	0.7
Cystic lesion with right axillary lymph node	2	1.4
Cystic lesion with right axillary lymph node	2	1.4
Ductal ectasia	10	7.1
Ductal ectasia cystic lesion with left axillary lymph node	1	0.7
Ductal ectasia hypoechoic nodules cystic lesion with left axillary lymph node	1	0.7
Ductal ectasia with left axillary lymph nodes	1	0.7
Ductal ectasia with right axillary lymph node	2	1.4
Echogenic nodule	5	3.6
Fibroadenoma	5	3.6
Fibroadenoma with intramammary lymph node	1	0.7
Hypoechoic nodules	11	7.9
Hypoechoic nodules with ductal ectasia	1	0.7
Hypoechoic nodules with right axillary lymph node	1	0.7
Left axillary lymph node	6	4.3
Lymph nodes	2	1.4
Macro calcifications	1	0.7
Macro calcifications with hypoechoic nodule.	1	0.7
Right axillary lymph node	11	7.9
Right Intramammary lymph node	1	0.7
Solid lesion	27	19.3
Solid lesion with micro calcifications	1	0.7
Total	138	100.0

## Discussion

Breast ultrasound has gained overall importance as a tool for the diagnosis of breast diseases in women. It would be more convenient the correlation of ultrasonography findings with the corresponding histopathological features. This study was done by using Ultrasound with 7-13 MHz of transducer. Data of 138 patients were recorded in this study. Ultrasound was done, and the findings were analyzed. Out of 138 patients, The Ultrasonographic findings and frequency came out to be: respectively, Calcific foci 1, Cystic lesion 2, Hypoechoic nodules 1, Abscesses 1, Calcific foci 2, Calcific foci with right axillary lymph node 1, Cyst with ductal ectasia 1, Cystic lesion 29, Cystic lesion & calcific foci 1, Cystic lesion with ductal ectasia 4, Cystic lesion with intramammary lymph node 1, Cystic lesion with left axillary lymph node1, Cystic lesion with right

axillary lymph node 2, Cystic lesion with right axillary lymph node 2, Ductal ectasia 10, Ductal ectasia cystic lesion with left axillary lymph node 1, Ductal ectasia hypoechoic nodules cystic lesion with left axillary lymph node 1, Ductal ectasia with left axillary lymph nodes 1, Ductal ectasia with right axillary lymph node 2, Echogenic nodule 5, Fibroadenoma 5, Fibroadenoma with intramammary lymph node 1, Hypoechoic nodules 11, Hypoechoic nodules with ductal ectasia 1, Hypoechoic nodules with right axillary lymph node 1, Left axillary lymph node 6, Lymph nodes 2, Macro calcifications 1, Macro calcifications with hypoechoic nodule 1, Right axillary lymph node 11, Right Intra-mammary lymph node 1, Solid lesion 27, Solid lesion with micro calcifications 1. Out of 138, only 3 women were breast feeders. According to this study, 57 patients had left sided breast pathologies and 81 had right-sided breast pathologies. Different investigations proclaimed that these ultrasound highlights, for example, oval or round shape, upgrade or nonappearance of back acoustic highlights, parallel direction, encompassed edges, sudden interface, nonattendance of encompassing tissue modifications spoke to a kindhearted bosom injury, while, unpredictable shape, echogenic corona, back acoustic shadowing and variations from the norm of the encompassing tissue paying little respect to resound design were viewed as steady with a harmful sore. It is also true that not all carcinomas fulfill these criteria and some do only partially. We then compared the ultrasound results findings with other studies. As compared to the study done by Havin A, ninety three participants (52.5%) had cyclical breast pain while 84 participants (47.5%) had non-cyclical breast pain. The pain was on the right side in 32.8% of participants, in left side in 36.7% and bilateral in 30.5%. The pain was mild in 58.2% of participants, moderate in 30.5% and severe in 11.3%. The ultrasonic assessment of the affected breast classified the participants into 4 categories; normal (29.9%), tubular (18.6%), ductasia (18.6%) and mass (32.8%). Among the 58 participants having mass in the breast, 48.3% had cystic mass and 51.7% had solid mass. The mass was on the right side in 36.2%, in left side in 29.3% and bilateral in 34.5%. The ultrasonic features of the mass showed that 86.2% of cases were benign and 13.8% were intermediate.

## Conclusion

Palpable breast masses could easily be characterized and localize with the help of inexpensive and a more accessible ultrasound modality. It should be the first line investigation in women of all age.

## References

- BERRYHILL, G. E., GLOVICZKI, J. M., TROTT, J. F., AIMO, L., KRAFT, J., CARDIFF, R. D., PAUL, C. T., PETRIE, W. K., LOCK, A. L. & HOVEY, R. C. J. P. O. T. N. A. O. S. 2012. Diet-induced metabolic change induces estrogen-independent allometric mammary growth. 109, 16294-16299.
- CALEFFI, M., DUARTE FILHO, D., BORGHETTI, K., GRAUDENZ, M., LITTRUP, P., FREEMAN-GIBB, L., ZANNIS, V., SCHULTZ, M., KAUFMAN, C. & FRANCESCATTI, D. J. T. B. 2004. Cryoablation of benign breast tumors: evolution of technique and technology. 13, 397-407.
- CARTER, B. A., PAGE, D. L., SCHUYLER, P., PARL, F. F., SIMPSON, J. F., JENSEN, R. A. & DUPONT, W. D. J. C. 2001. No elevation in long-term breast carcinoma risk for women with fibroadenomas that contain atypical hyperplasia. 92, 30-36.
- CHALYA, P. L., MANYAMA, M., RAMBAU, P. F., KAPESA, A., NGALLABA, S. E., MASALU, N. & MABULA, J. B. J. T. J. O. H. R. 2016. Clinicopathological pattern of benign breast diseases among female patients at a tertiary health institution in Tanzania. 18.
- DEVOLLI-DISHA, E., MANXHUKA-KËRLIU, S., YMERI, H. & KUTLLOVCI, A. J. B. J. O. B. M. S. 2009. Comparative accuracy of mammography and ultrasound in women with breast symptoms according to age and breast density. 9, 131.
- DYRSTAD, S. W., YAN, Y., FOWLER, A. M., COLDITZ, G. A. J. B. C. R. & TREATMENT 2015. Breast cancer risk associated with benign breast disease: systematic review and meta-analysis. 149, 569-575.
- EL-WAKEEL, H. & UMPLEBY, H. J. T. B. 2003. Systematic review of fibroadenoma as a risk factor for breast cancer. 12, 302-307.
- HATIM, K. S., LAXMIKANT, N. S. & MULLA, T. J. I. J. O. R. I. M. S. 2017. Patterns and prevalence of benign breast disease in Western India. 5, 684-688.
- LARSEN, T., FAURSCHOU, J., BAK, M. & RYTTOV, N. J. U. F. L. 2003. Fibroadenoma of the breast--modern strategy of treatment. 165, 1979-1983.
- ONGORE, V. O., KUSA, G. B. J. I. J. O. E. & ISSUES, F. 2013. Determinants of financial performance of commercial banks in Kenya. 3, 237-252.

- PARKIN, D. M., BRAY, F., FERLAY, J. & PISANI, P. J. C. A. C. J. F. C. 2005. Global cancer statistics, 2002. 55, 74-108.
- PRASAD, N. & HOUSERKOVA, D. 2007a. A comparison of mammography and ultrasonography in the evaluation of breast masses. *Biomedical Papers of the Medical Faculty of Palacky University in Olomouc*, 151.
- PRASAD, N. & HOUSERKOVA, D. J. B. P. O. T. M. F. O. P. U. I. O. 2007b. A comparison of mammography and ultrasonography in the evaluation of breast masses. 151.
- RANGASWAMY, P. & RUBBY, S. A. J. I. S. J. 2016. Clinical study on fibroadenoma of the breast. 3, 1916-1919.
- RASHEED, A., SHARMA, S., MOHSIN-UL-RASOOL, B. S., HAFIZ, A. & BASHIR, N. 2014. A three year study of breast lesions in women aged 15-70 years in a tertiary care hospital. *Sch J App Med Sci*, 2, 166-168.
- SILVERA, S. A. N., ROHAN, T. E. J. B. C. R. & TREATMENT 2008. Benign proliferative epithelial disorders of the breast: a review of the epidemiologic evidence. 110, 397-409.
- VALEA, F. A. & KATZ, V. L. J. C. G. T. E. P., PA: MOSBY ELSEVIER 2007. Breast diseases: diagnosis and treatment of benign and malignant disease. 15.
- WELLINGS, S., JENSEN, H. & MARCUM, R. J. J. O. T. N. C. I. 1975. An atlas of subgross pathology of the human breast with special reference to possible precancerous lesions. 55, 231-273.
- ZHOU, W.-B., XUE, D.-Q., LIU, X.-A., DING, Q., WANG, S. J. J. O. C. R. & ONCOLOGY, C. 2011. The influence of family history and histological stratification on breast cancer risk in women with benign breast disease: a meta-analysis. 137, 1053-1060.