



Journal of Health and Medical Sciences

A, Kante, M, Daou, B, Coulibali, Jf, Uhl, V, Delmas, Jm, Chevallier, B, Ba, and N, Ongoiba. (2020), 3D Vector Reconstruction of the Atlas from Anatomical Sections of Korean Visible Human at the Laboratory of Clinical and Digital Anatomy of Paris Descartes University. In: *Journal of Health and Medical Sciences*, Vol.3, No.3, 260-269.

ISSN 2622-7258

DOI: 10.31014/aior.1994.03.03.121

The online version of this article can be found at:
<https://www.asianinstituteofresearch.org/>

Published by:
The Asian Institute of Research

The *Journal of Health and Medical Sciences* is an Open Access publication. It may be read, copied, and distributed free of charge according to the conditions of the Creative Commons Attribution 4.0 International license.

The Asian Institute of Research *Journal of Health and Medical Sciences* is a peer-reviewed International Journal. The journal covers scholarly articles in the fields of Medicine and Public Health, including medicine, surgery, ophthalmology, gynecology and obstetrics, psychiatry, anesthesia, pediatrics, orthopedics, microbiology, pathology and laboratory medicine, medical education, research methodology, forensic medicine, medical ethics, community medicine, public health, community health, behavioral health, health policy, health service, health education, health economics, medical ethics, health protection, environmental health, and equity in health. As the journal is Open Access, it ensures high visibility and the increase of citations for all research articles published. The *Journal of Health and Medical Sciences* aims to facilitate scholarly work on recent theoretical and practical aspects of Health and Medical Sciences.



ASIAN INSTITUTE OF RESEARCH
Connecting Scholars Worldwide



3D Vector Reconstruction of the Atlas from Anatomical Sections of Korean Visible Human at the Laboratory of Clinical and Digital Anatomy of Paris Descartes University

Kante A¹, Daou M², Coulibali B², Uhl. Jf¹, Delmas V¹, Chevallier JM¹, Ba B², Ongoiba N²

¹ Anatomy Laboratory, Paris 5 University, Paris, France.

² Laboratory of Anatomy, University of Sciences, Techniques and Technologies of Bamako, Mali.

Correspondence: Dr KANTE Abdoulaye, Teacher at the Faculty of Medicine and Odontostomatology of Bamako, Mali. Email: kanteim@yahoo.fr

Abstract

Aim: Carry out a 3D vector reconstruction of the atlas from the anatomical sections of the "Korean Visible Human" for educational purposes. **Material and methods:** The anatomical subject was a 33-year-old Korean man who died of leukemia. It measured 164 cm and weighed 55 kg. This man donated his body to science. Her body was frozen and cut into several anatomical sections after an MRI and CT scan. These anatomical sections were made using a special saw called a 0.2 mm thick cryomacrotome. Thus 8,100 cuts were obtained. Only the sections numbered 780 to 860 were used for our study. A segmentation by manual contouring of the different parts of the atlas was done using the software Winsurf version 3.5 on a laptop PC running Windows 7 equipped with a Ram of 8 gigas. **Results:** Our 3D vector model of the atlas is easy to manipulate using the Acrobat 3DPDF interface. The atlas accessible in a menu can be displayed, hidden or made transparent, and 3D labels are available as well as educational menus for learning anatomy. **Conclusion:** This original work constitutes a remarkable educational tool for the anatomical study of the atlas and can also be used as a 3D atlas for simulation purposes for training in therapeutic gestures.

Keywords: 3D Vector Modelling, Atlas, Digital Anatomy, Korean Visible Human

1. Introduction

Training in human anatomy is essential at all stages of medical practice: clinical examination, interpretation of medical images and surgery are based on knowledge of the anatomy of the human body. The acquisition of these skills is first theoretical then practical with dissection. Unfortunately, the provision of subjects for this stage of

learning by dissection remains problematic, in general in the countries of the South and in particular in Mali, sometimes letting certain professionals start their careers with little experience in this field.

Sectioned images of the human body are very useful because of their high resolutions and natural colors compared to CT scans and magnetic resonance imaging (Ackerman 1990). The images available include those from the Visible Human Project (VHP, male and female) conducted in the United States (Ackerman 1990); the Chinese human "Visible" (CVH, man and woman) (Cho Z. 2009); the Chinese virtual human (VCH, man and woman) (Cho, Calamate & al 2012.); and the Korean "Visible" woman (VK; whole male body, male head, and female pelvis) (Chung, Shin, Brown P & al 2015).

The sectioned images of the VHP, CVH and VK males were used in several ways: for the creation of atlases (Dai, Chung, Qu & al 2012), navigation software (Kim, Choi, Jeong & al 2008); (Park, Chung, Shin & al 2013) and the virtual dissection software (Park, Chung, Hwang & al 2005) and allowed access free and free to three-dimensional models in PDF atlas files (Park, Chung, Hwang & al 2005). In addition, cross-sectional images of VK have been used so that the radiology dose conversion coefficients are calculated virtually (Park, Chung, Hwang & al 2006). However, the use of prepared female sectioned images has been limited for the following reasons:

- In VHP images, degeneration of the uterus and ovaries was observed because the subject was post-menopausal (59 years), and the lateral edges of the two arms could not be used due to the subject's overweight.

The image quality was not optimal due to the limited performance of the digital camera and the personal computer used (Park, Chung, Shin & al 2009); (Quackenbush, Ratiu, Kerr & al 1996)

- In addition to this, gaps in the images appeared in the digital atlases.

In CVH and VCH images, small pixel size images (> 0.1 mm) and 24 bits color were made, but the colors of the living body could not be represented because a fixative had been injected into the body and a red dye was infused into the arteries (Schiemann, Freudenberg, Pflessler & al 2000). If there were high-quality sectional images of a whole male body, they would be very useful, like images of female bodies.

It is in this context that we initiated this work which is part of our science thesis on 3D vector reconstruction of the ventral region of the neck from anatomical sections of Korean Visible Human (KVH). This article deals with the 3D vector reconstruction of the atlas that is part of the cervical region.

2. Materials and Methods

Our study was carried out in the Development Research, Imaging and Anatomy Unit (URDIA) EA 4465 in the Clinical and Digital Anatomy laboratory of the University of Paris Descartes.

The anatomical sections of a 33-year-old Korean man who died of leukemia who donated his body were made in 2010 after an MRI and CT scan. A cryomacrotome made it possible to make cuts of 0.2 mm thick on the frozen body, ie 8,100 cuts. (Figure 1)

Only the sections numbered 780 to 860 were used for our study (Figure 2).

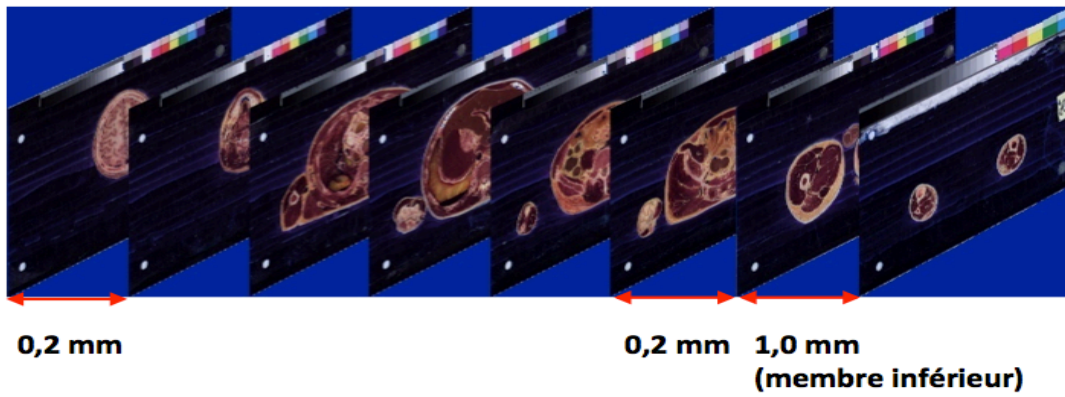


Figure 1: showing photographs of KVH anatomical sections

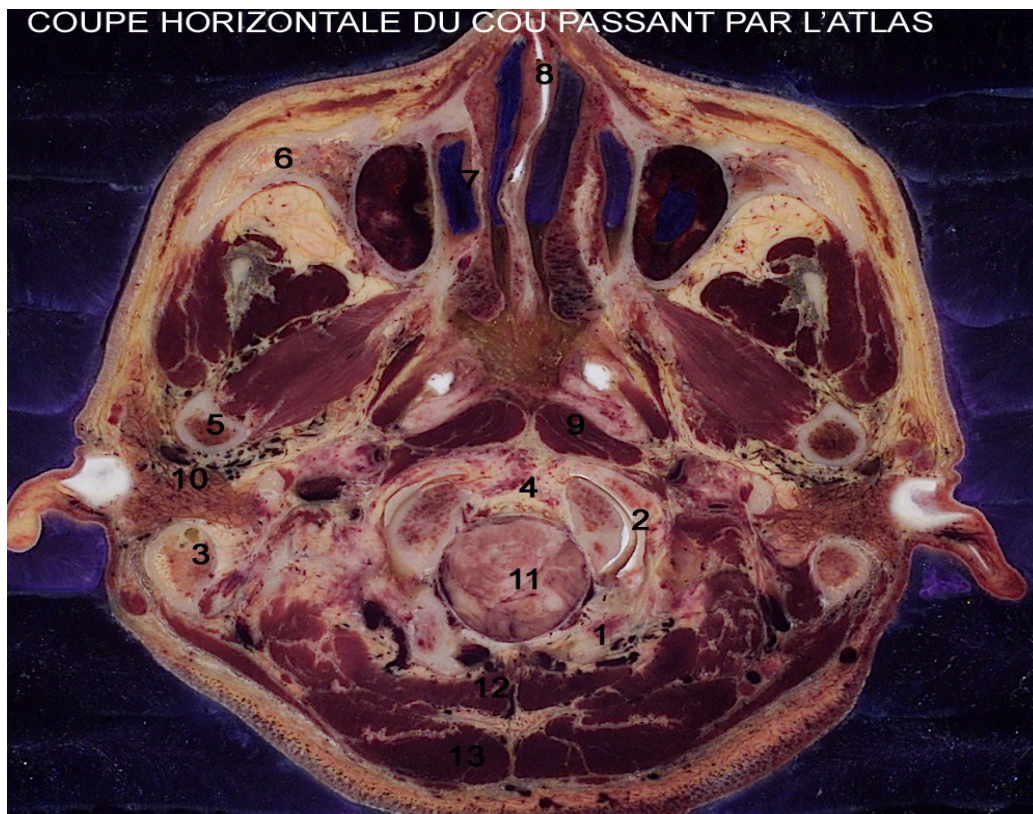


Figure 2: horizontal anatomical section passing through the first cervical vertebra or atlas

1. Occipital; 2. Occipito-atloid joint ; 3. Mastoid process; 4. Upper extremity of the odontoid process; 5. Mandible, 6. Zygomatic process 7. Nasal cavity; 8. Partition of the nasal cavity; 9. Anterior rectus muscle 10. Parotid gland; 11. Elongated marrow; 12. Semi-spiny muscle of the head; 13. Trapezius muscle.

A segmentation by manual contouring of the different parts of the atlas was done using the software Winsurf version 3.5 on a laptop PC running Windows 7 with a Ram of 8 gigas (Figure 3)

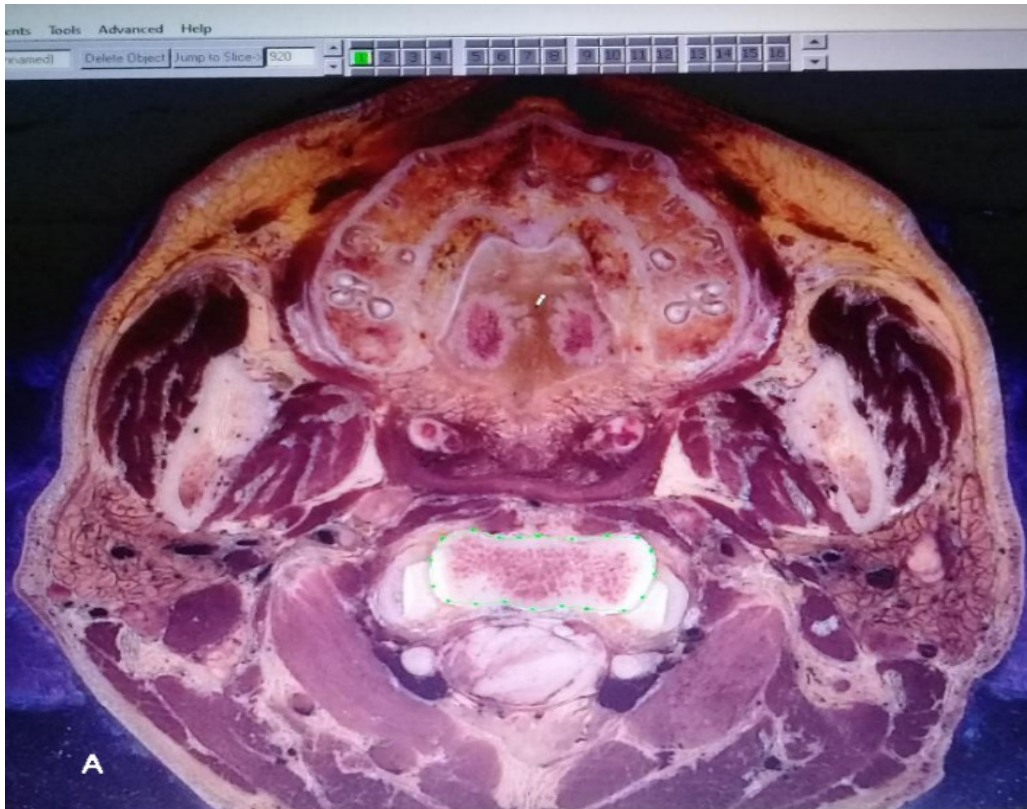

Figure 3: contouring the atlas on an anatomical section (2D) from Winsurf using the "pencil".

3. Result

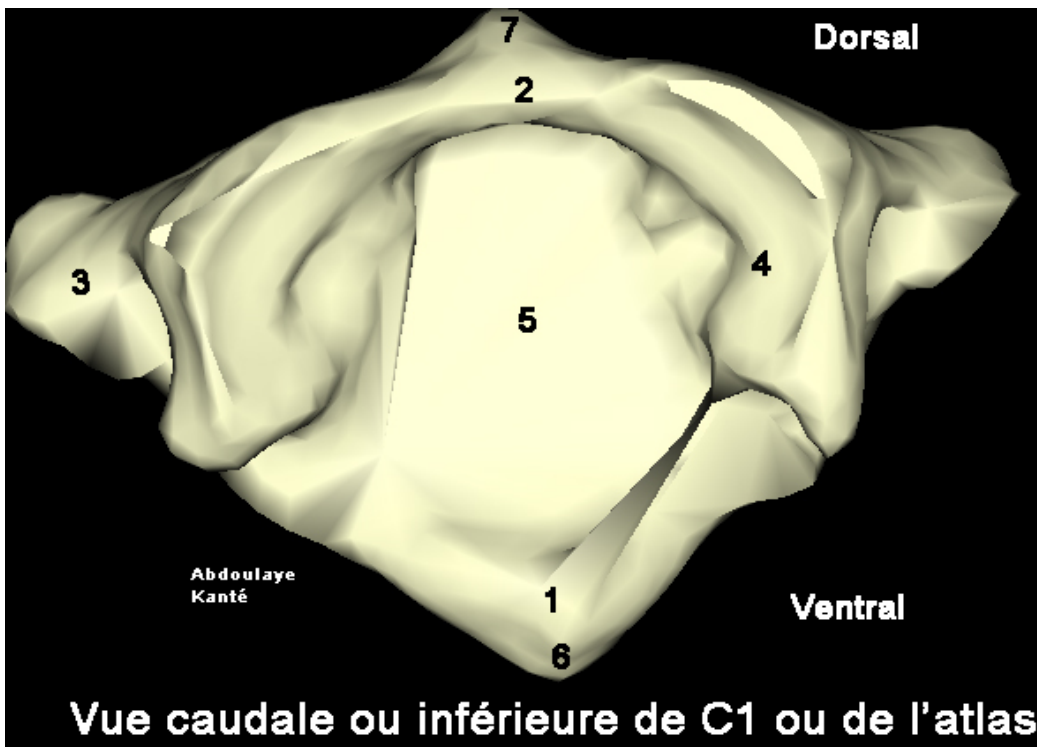


Figure 4: 3D vector reconstruction of the atlas with Winsurf software: caudal view

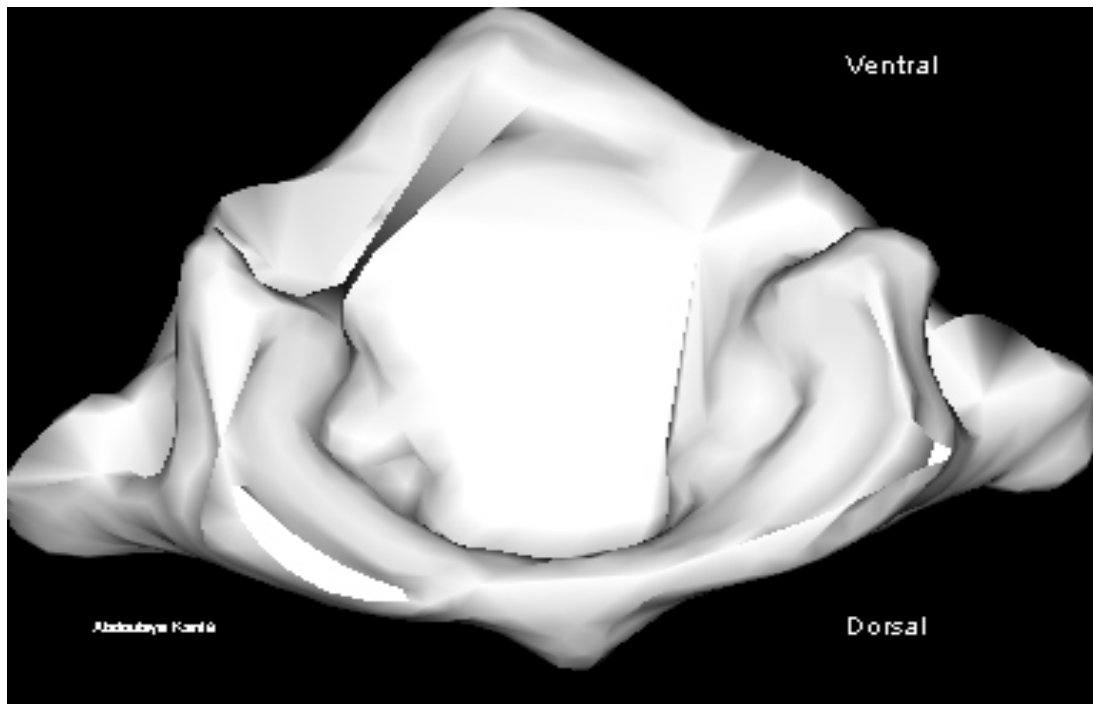


Figure 5 3D vector reconstruction of the atlas with Winsurf software :cranial view

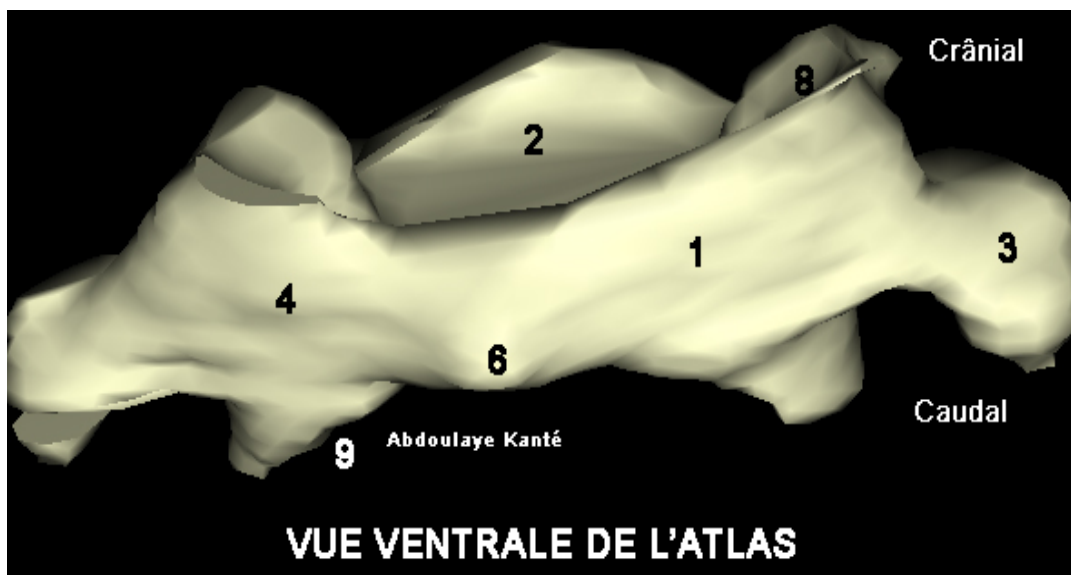


Figure 6 :3D vector reconstruction of the atlas with Winsurf software :ventral view

1.Belly arch; 2. Dorsal arch; 3. Transversal process; 4. Lateral weights; 5. Vertebral foramen; 6. Belly tuber; 7. Back tubercle; 8. Cranial articular facet; 9. Caudal articular facet.



Figure 7 : D vector reconstruction of the atlas with Winsurf software : lft side view

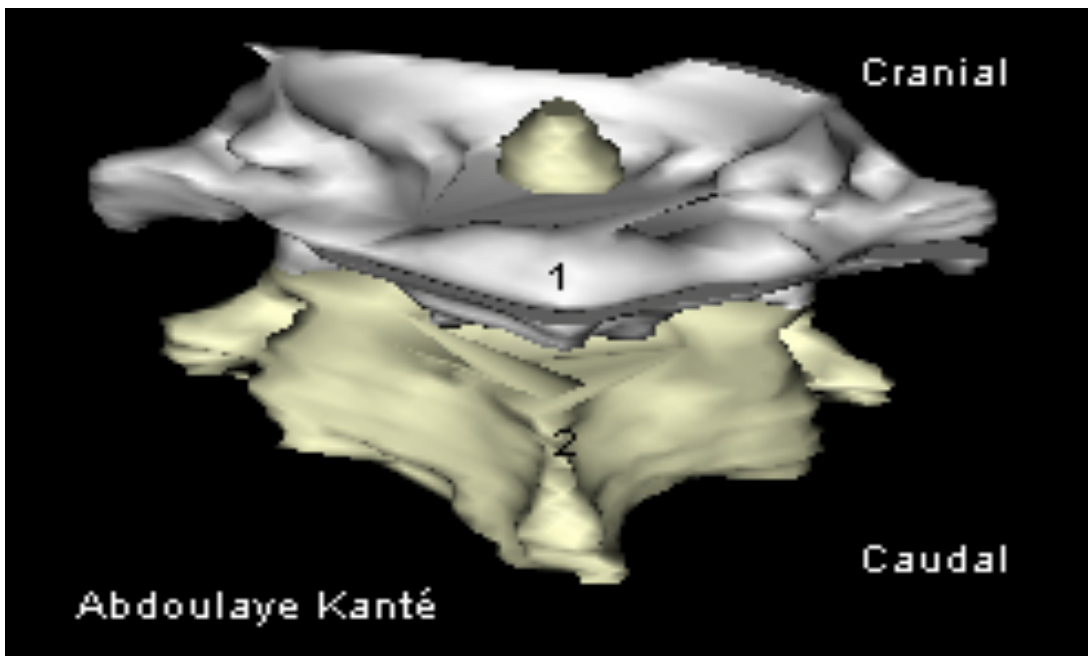


Figure 8 : 3 vector reconstruction of the atlas articulated with the axis with the Winsurf software :dorsal view

1. Atlas ; . Axis

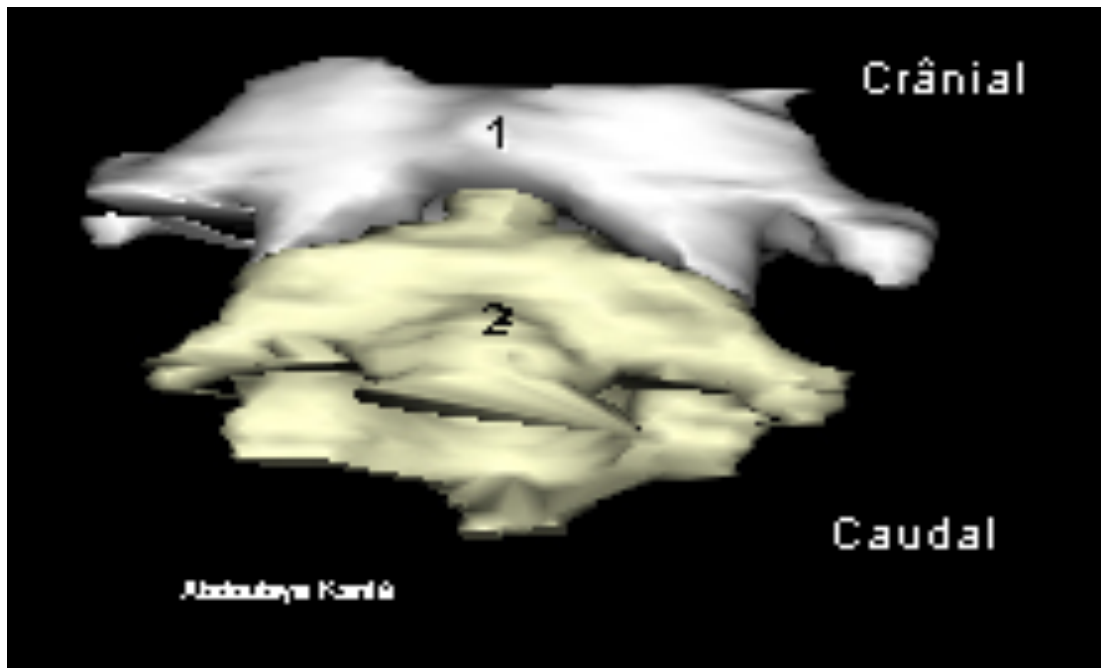


Figure 9 :3D vector reconstruction of the atlas articulated with the axis with the Winsurf software ventral view

1. Atlas 2. Axis

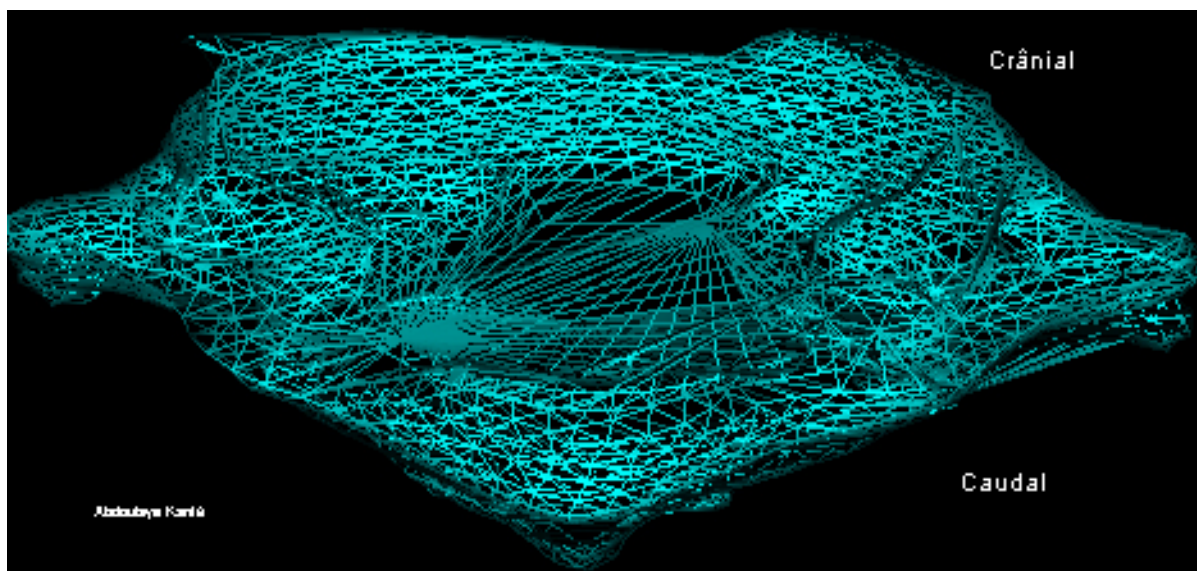


Figure 10 :3D vector reconstruction of the atlas articulated with the axis with the Winsurf software wireframe representation

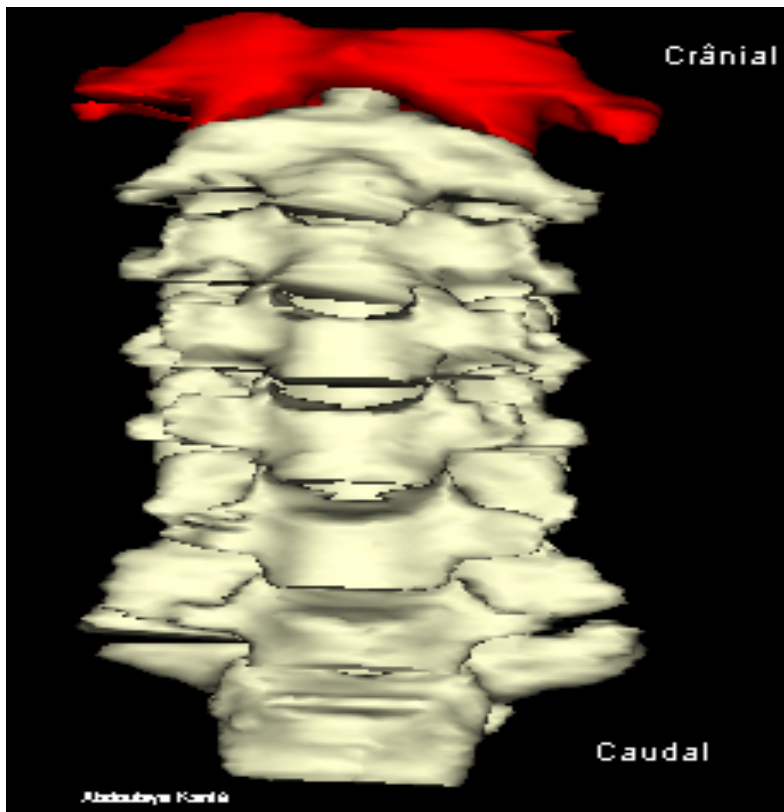

Figure 11 3D vector reconstruction of the atlas in red with the other cervical vertebrae with Winsurf software :ventral view

4. Discussion

This article was made from the anatomical sections of Korean Visible Human in order to achieve in the best possible way, a dynamic and detailed 3D atlas of the atlas.

Our work t,herefore c,onsisted in recognizing the anatomical structures of the atlas on these sections and in a more tedious work of contouring in order to obtain the most realistic models possible. Our methodology is quite similar to that of the Korean team, which used segmentation instead of manual contouring. (Figure 12)

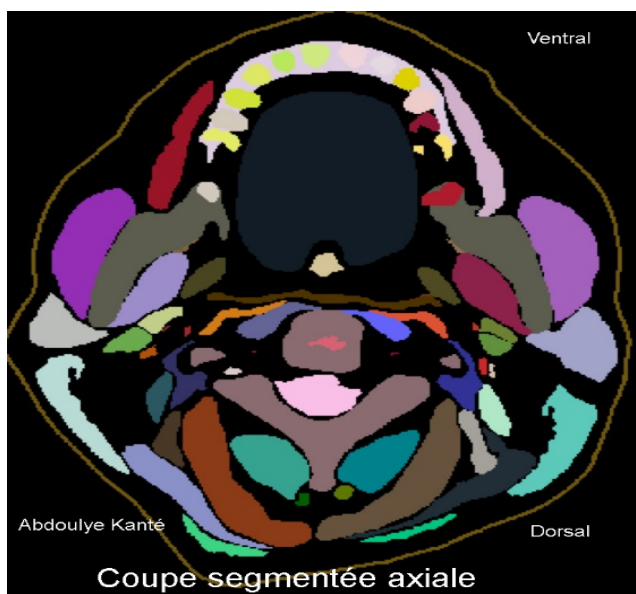


Figure 1 : segmented section used by the Korean team

The advantage of this work is essentially based on the fact that the entire contouring work and therefore the entire 3D vector reconstruction of the atlas, was carried out using real sections of the human body. This results in a major increase in the precision and reliability inherent in the results presented above.

Indeed, reconstructions of the atlas from digital procedures such as CT scans can prove to be somewhat disappointing in the sense that certain structures are absent and others that are difficult to distinguish. In contrast to this process, this contouring work is based on a manual, analog segmentation process under our supervision and not that of an automaton, which reduces the risk of anatomical errors in reconstruction.

The second advantage is based on the fact that better precision as well as the possibility of individualization of the different parts of the atlas favors a massive application in the university field thus participating in a better understanding by medical students and other fields. In addition, it is essential to underline that this application is not restricted to the university field but can also be the support of a "Surgical Training" thus allowing a continuous training of the surgeons and a fortiori an improvement of their aptitude in their practices daily.

Finally, it is clear that "Winsurf" and Acrobat 3D PDF are particularly easy to use software which is not the case with other 3D modeling and manual segmentation software. In addition, they offer fairly wide ranges of textures which further increase the realism that we can bring to our final work.

Although the "Winsurf" software made it possible to reproduce the typical cervical vertebra fairly faithfully, there are nevertheless some shortcomings.

The main disadvantage of this software is the time required to achieve the desired result. Indeed, this is a tedious contouring work of several months on several anatomical sections where sometimes only the section-by-section analysis was possible. To this are added the various objects that had to be created in order to be able to individualize the edges of the atlas, which increased the number of cuts to which it was necessary to return each time.

Unfortunately, there is no miracle cure allowing a reduction of this working time if it is not a great motivation and an unprecedented personal investment.

Conclusion

Our 3D vector modeling of the atlas is a remarkable educational tool for teaching the anatomy of the atlas and can also be used as a 3D atlas for simulation purposes for training in therapeutic gestures.

Conflicts of interest :

The authors do not declare any conflict of interest concerning the publication of this document.

References

- Ackerman M. J. The Visible Human project. A resource for education. *Acad Med.*1990;74(6):667-70.
- Cho Z. H. 7.0 Tesla MRI Brain Atlas, In Vivo Atlas with Cryomacrotome Correlation. *Springer, New York.*2009
- Cho Z. H; Calamate F; Chi JG. 7.0 Tesla MRI brain white matter atlas. *Panmun, Seoul.*2012
- Chung BS ; Shin DS ; Brown P ; Choi J ; Chung MS. Virtual dissection table including the Visible Korean images, complemented by free software of the same data. *Int J Morphol.* 2015 ;33(2):440-45
- Dai JX ; Chung MS ; Qu RM ; Yuan L ; Liu SW ; Shin DS. The Visible Human Projects in Korea and China with improved images and diversives applications. *Surg.Radiol.Anat.* 2012 ;34(6):527-34.
- Kim CH ; Choi SH ; Jeong JH ; Lee C ; Chung MS ; HDRK-Man. A whole-body voxel model based on high-resolution color slice images of a Korean adult male cadaver. *Phys Med Biol.*2008;53(15):4093-106.
- Park HS ; Chung MS ; Shin DS ; Jung YW ; Park JS. Accessible and informative sectioned images, color-coded images, and surface models of the ear. *Anat Rec.*2013;296(8):1180-86.
- Park JS ; Chung MS ; Hwang SB ; Lee YS ; Har DH ; Park HS. Visible Korean Human:Improved serially sectioned images of the entire body. *IEEE Trans.Med.Imaging.* 2005;24(3):352-60.

- Park JS ; Chung MS ; Hwang SB ; Lee YS ; Har DH ; Park HS. Technical report on semiautomatic segmentation by using the Adobe Photoshop.*J Digit Imaging*.2005;18(4):333 -43.
- Park JS ; Chung MS ; Hwang SB ; Shin BS ; Park HS. Visible Korean Human : Its techniques and applications.*Clin Anat*. 2006;19(3):216-24.
- Park JS ; Chung MS ; Shin DS ; Har DH ; Cho Z.H ; Kim YB ; Han JY ; Chi J.G. Sectioned images of the cadaver head including the brain and correspondences with ultrahigh field 7.0 T MRIs.*Proc IEEE*.2009;97(12):1988-96.
- Quackenbush D ; Ratiu P ; Kerr,J. Segmentation of the Visible Human Data Sets.*The Visible Human Project Conference Proceedings*. October 1996:7-8.
- SchiemannT ; Freudenberg J ; Pflesser B ; Pommert A ; Priesmeyer K ; Riemer M ; Schubert R ; Tiede U ; Höhne KH. Exploring the Visible Human using the VOXEL-MAN framework. *Comput Med Imaging Graph*.2000;24(3):127-32.